

Compliance Guideline for Training Establishment Carcass Sorters in the  
New Poultry Inspection System (NPIS)  
Food Safety and Inspection Service  
U.S. Department of Agriculture  
September 2014

Table of Contents

I. PURPOSE .....	3
II. BACKGROUND .....	3
III. GUIDANCE FOR SORTER TRAINING PROGRAMS .....	4
A. Training Program Elements .....	4
B. Carcass Disposition and Sorting Procedures .....	6
IV. NORMAL CARCASSES, PARTS, AND VISCERA .....	7
A. General Features .....	7
B. Skin .....	8
C. Air sacs .....	9
D. Liver .....	9
E. Heart.....	10
F. Spleen .....	10
G. Joints, Tendons, and Bone Marrow .....	10
V. GENERALIZED CONDITIONS REQUIRING WHOLE BIRD DISPOSAL .....	11
A. Septicemia/Toxemia .....	11
B. Cadaver .....	13
C. Dead on Arrival (DOA).....	14
D. Leukosis .....	19
VI. LOCALIZED DISEASE OR OTHER CONDITIONS AFFECTING POULTRY CARCASSES .....	21
A. Contamination .....	21
B. Keratoacanthoma and Other Tumors.....	22
C. Airsacculitis .....	19
D. Inflammatory Process.....	21
E. Turkey Osteomyelitis Complex .....	22

F. Synovitis .....	30
G. Mutilation.....	32
H. Overscald .....	33
I. Ascites .....	33
J. Breast Atrophy .....	34
K. Turkey Leg Edema .....	34
L. Bruises.....	34
M. Parts Disposition .....	36
Appendix: ANATOMY OF POULTRY.....	42

## I. PURPOSE

This compliance guideline would help poultry slaughter establishments train their employees to conduct the carcass and associated viscera sorting activities that are required under the New Poultry Inspection System (NPIS).

## II. BACKGROUND

The Food Safety and Inspection Service (FSIS) published a final rule

<http://www.fsis.usda.gov/wps/wcm/connect/00ffa106-f373-437a-9cf3-6417f289bfc2/2011-0012F.pdf?MOD=AJPERES>;

to establish a new inspection system called the NPIS. Under the NPIS establishment personnel are required to sort carcasses and remove unacceptable carcasses and parts before the birds are presented to the FSIS online carcass inspector. FSIS believes that training of establishment sorters is vitally important to ensure that they are able to properly perform their duties under the NPIS. Therefore, FSIS has developed guidance documents to assist establishments in the training of their carcass sorters. This guidance is based on the training that FSIS provides to its online inspection personnel, who are responsible for sorting carcasses under the existing inspection systems. The Agency is posting this guidance material on the FSIS Web site:

<http://www.fsis.usda.gov/wps/portal/fsis/topics/regulatory-compliance/compliance-guides-index> and announcing the availability of such materials through the FSIS Constituent Update. This Compliance Guideline articulates how establishments can meet FSIS expectations regarding sorting activities under the NPIS.

It is important to note that this Guidance represents FSIS's current thinking on this topic and should be considered useable as of this issuance.

### Request for Comments:

FSIS is seeking comments on this guidance document. All interested persons may submit comments regarding any aspect of this document, including but not limited to: content, readability, applicability, and accessibility. FSIS will update these guidelines in response to any comments that it receives and as needed to reflect the most current information available to FSIS and stakeholders. The comment period will be 60 days.

Comments may be submitted by either of the following methods:

Federal eRulemaking Portal: This Web site provides the ability to type short comments directly into the comment field on this Web page or attach a file for lengthier comments. Go to <http://www.regulations.gov> and follow the online instructions at that site for submitting comments.

Mail, including CD-ROMs, and hand- or courier-delivered items: Send to Docket Clerk, U.S. Department of Agriculture, Food Safety and Inspection Service, Patriots Plaza 3, 1400 Independence Avenue, SW, Mailstop 3782, Room 8-163A, Washington, DC 20250-3700.

Instructions: All items submitted by mail or electronic mail must include the Agency name, FSIS, and document title: FSIS Compliance Guideline for Training Establishment Carcass Sorters in the New Poultry Inspection System (NPIS). Comments received will be made available for public inspection and posted without change, including any personal information, to <http://www.regulations.gov>.

### III. GUIDANCE FOR SORTER TRAINING PROGRAMS

#### A. Training Program Elements

This compliance guideline recommends training elements and post-mortem inspection standards that FSIS has found effective in training FSIS online inspectors to identify carcasses and parts exhibiting condemnable conditions that are unwholesome and unfit for human food. Poultry slaughter establishments can use the information in this guideline to train establishment employees that would conduct sorting activities under the NPIS.

As stated previously this compliance guideline is based on FSIS training materials for its online inspectors which are available at:

<http://www.fsis.usda.gov/wps/portal/fsis/topics/inspection/workforce-training/regional-on-site-training>;

These training materials can be a valuable resource for additional details and background, such as providing a module for familiarizing employees with the steps in the slaughter process. Training objectives, workshops and evaluation tests are also provided in the training.

Proper training is important to establishment sorters' ability to make accurate decisions on how to address carcasses exhibiting condemnable conditions. Under the NPIS, if sorters do not make these decisions correctly, FSIS inspection personnel are required to take actions such as stopping the production line to remove contaminated carcasses, issuing non-compliance records, and directing the establishment to reduce the line speed to ensure that the establishment is able to maintain process control, and that the online carcass inspector is able to conduct a carcass by carcass inspection.

A single training method or program may not be applicable to all establishments. Individual establishments should design training programs consistent with the operational conditions in the establishment.

FSIS recommends that each establishment develop a standardized training program for its sorters to enable them to properly identify and dispose of carcasses and parts exhibiting condemnable conditions to ensure that carcasses and parts are not used as human food. FSIS recommends the following types of training as effective elements of a sorter training program:

- **Classroom** or offline training is a lecture type presentation that provides essential information for sorters to be able to:
  - recognize and name common parts of poultry carcasses and organs;

- recognize and name common conditions affecting poultry carcasses and viscera;
- differentiate among normal, localized, and generalized conditions affecting poultry carcasses and viscera;
- determine the disposition of each carcass and viscera and take appropriate actions to ensure removal and disposal of unwholesome and unfit carcasses, parts, or viscera to ensure they can not be used as human food; and
- take appropriate recording actions.

**NOTE:** An exam or self-assessment for trainees may be helpful to measure and quantify understanding and comprehension of training.

- **Wet lab** is an offline training activity that provides trainees with practical application of what they have learned in classroom training. Features include:
  - using real examples of carcasses and parts –both normal and abnormal;
  - performing hands on practice prior to beginning normal duties online to identify carcass conditions and make dispositions;
  - acting on carcass disposition made; and
  - recording actions.
- **On the job training** is to practice what has been learned in lecture including:
  - performing sorting at production rates;
  - identifying carcass, parts, and viscera dispositions;
  - receiving real time feedback from supervisors; and
  - taking appropriate actions as determined necessary.
- **Follow up sessions** (called correlations) are to reinforce previous learning. Features include:
  - conducting these sessions at a set regular frequency,
  - discussing regularly standardized procedures to make decisions to identify and properly dispose of carcasses on a continuous basis at production rates; and
  - describing reasons for making dispositions and appropriate actions.
- **Continuous monitoring** of individual employee performance to maintain skill level

If questions related to dispositions arise establishment management may contact the FSIS public health veterinarian (PHV) or send questions to askFSIS.

( <http://askfsis.custhelp.com/>; )

## B. Carcass Disposition and Sorting Procedures

The purpose of carcass sorting is to separate carcasses, parts and viscera that are unwholesome and unfit for human food from those that are fit for human food. When carcasses and parts exhibiting condemnable conditions are identified, they would be properly disposed to ensure they are not used as human food.

Through observation and occasional touching of the carcass and viscera, sorters make decisions called dispositions of each carcass, part, or viscera. Dispositions are based on the stage of the disease and to what degree, if any, the bird is recovering from the disease at the time the bird is slaughtered. If a disease process or injury exists in the live bird, the disease will stop progressing at the time of slaughter, but the visible changes (lesions) in the bird caused by the illness or injury will remain. The more severely affected a bird is, the more likely the whole carcass is unwholesome.

Under the NPIS, the establishment sorter would make a decision about the wholesomeness and fitness of each carcass and viscera and properly dispose of unwholesome carcasses, parts and viscera to ensure they are not used as human food.

- If the carcass and viscera appear wholesome, they would be allowed to continue down the line to the FSIS carcass inspector located at the end of the line.
- If the carcass is wholesome except for localized conditions that can be removed, those portions of the carcass exhibiting condemnable conditions would be removed and disposed of properly. The rest of the carcass is wholesome and would proceed down line to the FSIS online carcass inspector.
- **Localized conditions** means one or more conditions exist in the carcass or viscera, but each condition affects only one particular part and does not relate to the other parts of the carcass or viscera. The localized portions of carcasses, parts, and viscera are unwholesome and unfit and actions may be taken to trim, salvage or reprocess locally affected carcasses either on the line or off the line. The affected tissues that are unwholesome would be removed and disposed of properly as described above.
- **Generalized conditions** include conditions that have affected the carcass to the extent that much of the carcass is affected and cannot be trimmed or salvaged. Carcasses and viscera affected with generalized disease conditions are unwholesome and unfit for human food and should be disposed of properly. (In some cases, the viscera may be saved for human food.)
- **Generalized conditions** also include those conditions that make the entire carcass and viscera unwholesome, and the carcass and viscera must be properly disposed to ensure that they are not used as human food.
- Finally, **generalized conditions** also include disease conditions that produce **systemic change** in birds. Those carcasses and viscera show certain obvious changes (see section **V. A. Septicemia and Toxemia**) that affect the whole

carcass. Carcasses showing systemic change may also exhibit a localized condition. In either case any carcasses showing systemic change would require proper disposal of the entire carcass and viscera to ensure they are not used as human food.

- If the carcasses exhibit conditions that are **questionable** and require further review, then the carcasses could be placed on a holding rack for further review by establishment supervisors or team leaders.

This compliance guideline includes an appendix to be used as resources to assist establishments in the training of sorters. **Appendix: Anatomy of Poultry** is provided for establishment sorters to recognize common parts of the poultry carcass, skeleton, and digestive tract.

**Image Descriptions** are provided in the text of this guide to describe the conditions of carcasses and parts shown in each image. The descriptions are under each image and a list of the descriptions is also located at the end of this document.

FSIS has found that using standardized procedures and thought processes result in effective and accurate sorting on a continuous basis. A single sorting procedure or thought process may not be applicable to all establishments.

FSIS recommends that sorters on a moving line use standardized procedures to enable them to make accurate dispositions on a continuous basis.







## **IV. NORMAL CARCASSES, PARTS, AND VISCERA**

### **A. General Features**

Knowing how normal carcasses, parts, and viscera appear is necessary to accurately identify carcasses, parts, or viscera that are abnormal. Diseases and other abnormalities produce visible changes to poultry carcasses. Poultry carcasses that are normal can look different from each other because of their age, breed, diet and the slaughter practices of the establishment. Normal young chickens and turkeys will have healthy skin, firm muscles, and fat in the flaps, the gizzard and around the heart. There may be some slight color changes to the skin of the drumstick and thigh and sometimes in the fat inside their bodies. The best way to learn what is normal is to look at birds under the direction of establishment supervisors or lead team members.

**Normal** carcasses, parts, and viscera are not affected with disease or other conditions. If the carcass is wholesome and normal without any localized or generalized disease or other conditions, it would be allowed to continue down the line to the FSIS online carcass inspector.




The following images show normal carcasses.


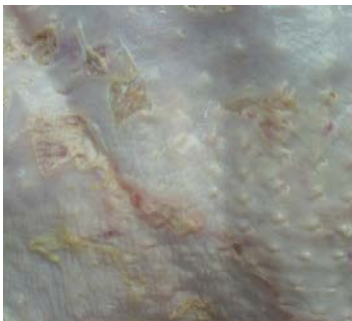

		
<p>10-1822</p> <p>This is a well-nourished young chicken with ample body fat and no obvious blemishes. The body is plump. The general form of the wings and hips is round. The skin appears uniform in color, moist, and thick. The underlying muscle tissue is barely visible through the skin.</p>	<p>07-0877</p> <p>This is a well-nourished young chicken with ample body fat and minimal blemishes. The body is plump. The general form of the wings and hips is round. The skin appears uniform in color, moist, and thick. The underlying muscle tissue is barely visible through the skin. The yellow color is due to yellow plant pigments in the feed.</p>	<p>10-1846</p> <p>This is an adequately nourished young chicken with adequate body fat and minimal blemishes. The body is slender. The general form of the wings and sternum is angular. The skin appears uniform in color, moist, and thin. The underlying muscle tissue is visible through the skin.</p>
		
<p>10-1320</p> <p>This is a well-nourished young turkey with ample body fat and minimal blemishes. The body is plump. The general form of</p>	<p>10-1324</p> <p>This is a well-nourished young turkey with ample body fat and minimal blemishes. The body is plump. The general form</p>	<p>10-1318</p> <p>This is an adequately nourished young turkey with adequate body fat and minimal blemishes. The body is slender. The general form</p>






the wings and hips is round. The skin appears uniform in color, moist, and thick. The underlying muscle tissue is barely visible through the skin.	of the wings and hips is round. The skin appears uniform in color, moist, and thick. The underlying muscle tissue is barely visible through the skin.	of the wings and sternum is angular. The skin appears uniform in color, moist, and thin. The underlying muscle tissue is visible through the skin.
----------------------------------------------------------------------------------------------------------------------------------------------------	-------------------------------------------------------------------------------------------------------------------------------------------------------	----------------------------------------------------------------------------------------------------------------------------------------------------

## B. Normal Skin

		
06-0316 The skin of this young chicken appears uniform in color, moist, and thick. Feather follicles appear uniform in size and arranged in rows with approximately equal space between follicles. The minor quality defects – feather remnant and scratches – do not make the skin unsafe or unfit for human food.	10-0403 The skin of this young chicken appears uniform in color, moist, and thick. Feather follicles appear uniform in size and arranged in rows with approximately equal space between follicles. The minor quality defects – feather remnants and red blemishes – do not make the skin unsafe or unfit for human food.	10-1161 The skin of this young chicken appears uniform in color, moist, and thick. Feather follicles appear uniform in size and arranged in rows with approximately equal space between follicles. The minor quality defects – red blemishes – do not make the skin unsafe or unfit for human food.

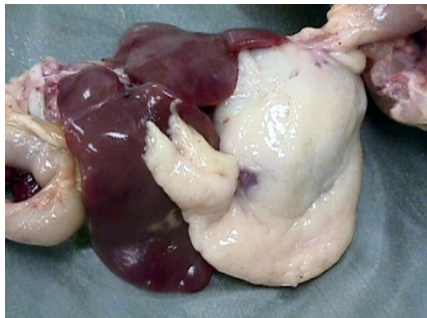
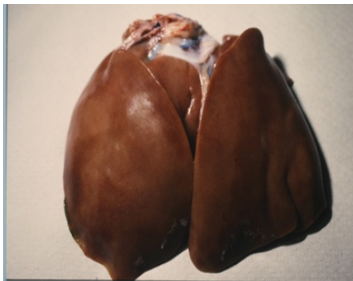

		
<p style="text-align: center;"><b>10-1465</b></p> <p>This is a well-nourished young chicken with ample body fat and no obvious blemishes. The skin appears uniform in color, moist, and thick. Feather follicles appear uniform in size and arranged in rows with approximately equal space between follicles.</p>	<p style="text-align: center;"><b>10-1532</b></p> <p>The skin of this young turkey appears uniform in color, moist, and thick. Feather follicles appear uniform in size and arranged in rows with approximately equal space between follicles. The minor quality defects – surface blemishes – do not make the skin unsafe or unfit for human food.</p>	<p style="text-align: center;"><b>10-1606</b></p> <p>The skin of this young turkey appears uniform in color, moist, and thick. Feather follicles appear uniform in size and arranged in rows with approximately equal space between follicles. The minor quality defects – retained cuticle and feather remnant – do not make the skin unsafe or unfit for human food.</p>

### C. Normal air sacs

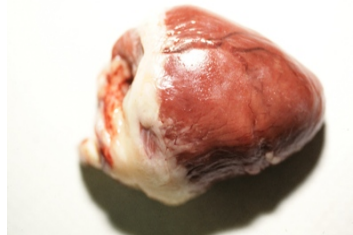

		
<p style="text-align: center;"><b>10-2223</b></p> <p>The normal thoracic and abdominal air sacs in this young turkey appear thin, pliable, and somewhat</p>	<p style="text-align: center;"><b>10-1044</b></p> <p>The normal thoracic air sac in this young chicken appears thin, pliable, and somewhat transparent.</p>	<p style="text-align: center;"><b>10-1046</b></p> <p>The normal thoracic air sac in this young chicken appears thin, pliable, and somewhat transparent.</p>

transparent.	The minor quality defect – lung – does not make the carcass unsafe or unfit for human food.	
--------------	---------------------------------------------------------------------------------------------	--

#### D. Normal Liver



		
<p>10-1807</p> <p>This normal liver in a young chicken appears reddish-purple with light spots and blotches. The general outline is a smooth, unbroken curve. The texture of a normal liver is firm. The normal fat attached to the gizzard appears uniformly white and completely opaque.</p>	<p>06-0228</p> <p>This normal liver in a young turkey appears brown with light spots and blotches. The general outline is a smooth, unbroken curve. The texture of a normal liver is firm.</p>	<p>09-0690</p> <p>These normal livers from two young turkeys appear reddish-brown with light spots and blotches. The general outline is a smooth, unbroken curve. The dry appearance of the liver on the left is a post mortem artifact. The texture of a normal liver is firm.</p>

#### E. Normal Heart

		
-------------------------------------------------------------------------------------	-------------------------------------------------------------------------------------	---------------------------------------------------------------------------------------




<p style="text-align: center;">07-0159</p> <p>This normal heart in a young chicken appears reddish-tan with uniformly white fat where the arteries and veins attach. The surface color appears uniform. The general outline is a smooth, unbroken curve except where the arteries and veins attach.</p>	<p style="text-align: center;">03-0732</p> <p>This normal heart in a young turkey appears red with uniformly white fat where the arteries and veins attach. The surface exhibits spots and blotches. The general outline is a smooth, unbroken curve except where the arteries and veins attach.</p>	<p style="text-align: center;">09-0691</p> <p>These two normal hearts from two young turkeys appear red with uniformly white fat where the arteries and veins attach. The surface exhibits spots and blotches. The general outline is a smooth, unbroken curve except where the arteries and veins attach.</p>
---------------------------------------------------------------------------------------------------------------------------------------------------------------------------------------------------------------------------------------------------------------------------------------------------------	------------------------------------------------------------------------------------------------------------------------------------------------------------------------------------------------------------------------------------------------------------------------------------------------------	----------------------------------------------------------------------------------------------------------------------------------------------------------------------------------------------------------------------------------------------------------------------------------------------------------------

## F. Normal Spleen

		
<p style="text-align: center;">07-0242</p> <p>These normal spleens from young chickens are round to oval. Their color varies from red to tan. The surface color appears uniform or exhibits spots and blotches.</p>	<p style="text-align: center;">09-0693</p> <p>These normal spleens from young turkeys are round to oval. Their color varies from red to tan. The surface color appears uniform or exhibits spots and blotches.</p>	



## G. Normal Joints, Tendons, and Bone Marrow

		
10-1232	10-0236	09-0794
This normal joint surface and tendon in a young turkey are white. The surface is shiny.	This normal joint surface and tendon in a young chicken are white. The surface is shiny.	This normal bone marrow from a young turkey appears uniformly red with a fine texture.

## V. GENERALIZED CONDITIONS REQUIRING WHOLE BIRD DISPOSAL

### A. Septicemia/Toxemia

Septicemia/toxemia (Sep/Tox) is caused by disease-producing bacteria and their toxins in the blood which produce systemic change in the bird. Systemic change affects the body as a whole, rather than localized portions of it. The systemic changes found in Sep/Tox are the result of the bird's organ systems not working properly. Cells weaken allowing blood to leak out of vessels (hemorrhage) into the viscera organs (liver, spleen, kidneys) and muscles of the bird. Other changes cause drying out (dehydration) of the skin and muscle wasting.

Sep/Tox carcasses are usually dark in color with dark reddish viscera, especially the gizzard and heart fat. Other fat may also have an abnormal color ranging from pale to brownish red. The kidneys, liver, and spleen may appear swollen. Inside the cavity of the carcass small amounts of fluid mixed with blood may be found.

In both eviscerated (opened to remove the guts) and non-eviscerated carcasses, the skin and muscle will appear dark or blue and have a dried appearance (dehydrated). The carcasses may also show muscle breakdown or wasting which gives a shrunken appearance especially to the breast muscles. The keel bone may be seen sticking out from beneath the skin of the breast muscles.

If a carcass shows systemic change (Sep/Tox), as described above, it is unwholesome and must be disposed of properly to ensure the carcass and its viscera are not used as human food. However, not every carcass affected with Sep/Tox will show all of these signs.

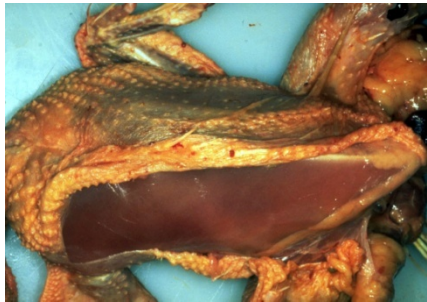


If carcasses are affected with any other condition or disease and also shows signs of systemic change (Sep/tox), the carcass and its viscera must be disposed of properly to ensure they are not used as human food.



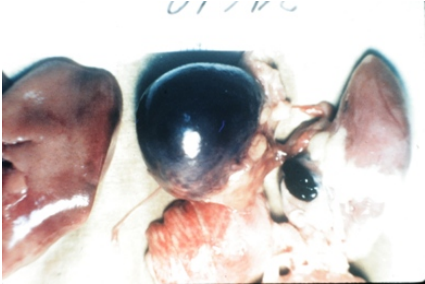
**What to Look For:**






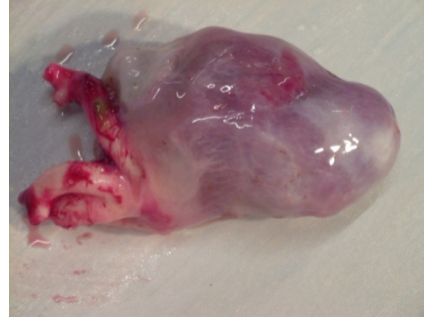
- carcass appears dark red, pale, or blue in color;
- severe drying out of the skin and muscle may be observed;
- liver, kidneys, and spleen are swollen and congested (filled up) with blood;
- carcass has generalized muscle wasting.

**Do not dispose of carcasses if:**

- only dark skin or meat is observed, and the rest of the carcass is normal;
- the birds are only small birds and have good fat color and healthy looking skin and meat (flesh); and
- the carcass appears only slightly dehydrated (the skin looks a little dry).

		
<p style="text-align: center;">10-1901</p> <p>This young chicken evidences adequate body fat and normal skin. The uniformly dark muscle tissue is suggestive of an extreme loss of body fluids, which is consistent with a generalized disease condition.</p>	<p style="text-align: center;">04-0536</p> <p>This young chicken evidences necrosis and hemorrhage in the liver and spleen. The liver appears reddish-brown. The general outline is a smooth, unbroken curve. The linear white areas are soft and suggestive of dead tissue. The dark red areas in the liver and dark purple spleen are characteristic of hemorrhage. The parallel orientation of the white and dark red tissue in the liver is</p>	<p style="text-align: center;">07-0564</p> <p>This young chicken evidences hemorrhage in the heart. The general outline is a smooth, unbroken curve except where the arteries and veins attach. The dark red surface blotches are characteristic with hemorrhage, which is consistent with a generalized disease condition.</p>

	suggestive of swelling caused by the liver pressing against the ribs. Necrosis and hemorrhage are consistent with a generalized disease condition.	
		
<p>10-2017</p> <p>This young chicken evidences necrosis in the liver. The liver appears red. A significant portion of the liver is pink. Exudates are visible on the surface. The general outline is a smooth, unbroken curve. Necrosis with exudates is consistent with a generalized disease condition. The yellow color of the fat is due to yellow plant pigments in the feed.</p>	<p>09-0625</p> <p>This young turkey evidences necrosis in the liver. The liver appears red. The general outline is a smooth, unbroken curve. The linear white areas are soft and suggestive of dead tissue. The parallel orientation of the white tissue is suggestive of swelling caused by the liver pressing against the ribs. Necrosis is consistent with a generalized disease condition.</p>	<p>09-0921</p> <p>This young chicken evidences necrosis in the liver and hemorrhage in the spleen. The liver is soft with white blotches suggestive of dead tissue. The general outline is a smooth, unbroken curve. The dark purple and soft spleen is characteristic of hemorrhage. The heart appears normal. Necrosis and hemorrhage are consistent with a generalized disease condition.</p>

		
<p>07-0851</p> <p>This young chicken evidences adequate body fat and normal skin. The enlarged joint at the end of the drumstick is suggestive of inflammation. The uniformly dark muscle tissue is suggestive of extreme loss of body fluids. Inflammation with loss of body fluids are compatible with wasting, which is a generalized disease condition.</p>	<p>10-1950</p> <p>This young chicken evidences inadequate body fat and normal skin. The prominent keel bone and uniformly dark muscle tissue are compatible with wasting, which is consistent with a generalized disease condition.</p>	<p>10-1257</p> <p>This young turkey evidences inadequate body fat and normal skin. The prominent thighbone and uniformly dark muscle tissue are compatible with wasting, which is consistent with a generalized disease condition.</p>
		
<p>10-1352</p> <p>This young turkey evidences inadequate body fat and normal skin. The linear, red blemishes in the skin are veins filled with blood. The prominent thighbone and uniformly dark muscle tissue</p>	<p>10-0866</p> <p>The fat attached to the gizzard of this young turkey appears thin, pink, and transparent. This is compatible with wasting, which is a generalized disease</p>	<p>10-0706</p> <p>The heart of this young turkey appears wet, and off-white. The fat, normally visible where the arteries and veins attach, is gone. The general outline is no longer a smooth, unbroken curve.</p>



are compatible with wasting, which is consistent with a generalized disease condition.	condition.	This is compatible with wasting, which is a generalized disease condition.
----------------------------------------------------------------------------------------	------------	----------------------------------------------------------------------------




## B. Cadaver

A cadaver is a generalized condition that causes the carcass and viscera to be unwholesome and unfit for human food. Cadavers are any birds that did not bleed out properly due to a poor or missed cut of the neck veins before the bird entered the scalding. The heat of the scalding causes blood left in the carcass to expand into the skin blood vessels, giving the skin of the carcass and neck a cherry red to purple color. The blood also accumulates in the dependent (lower) regions, such as the necks, wings, and upper breast area. Some cadavers may appear red all over; others will appear red only in the lower regions of the carcass. The blood vessels in the viscera will appear enlarged and the liver may appear burgundy colored. The entire carcass and viscera of cadavers are unwholesome and must be disposed of properly to ensure that they are not used as human food.

### What to Look For:

- cherry red to purple color of whole carcass or the lower regions of the carcass;
- sometimes, just the neck will appear cherry red or purple color;
- may be no cut on the neck, or may be only partially cut; and
- blood vessels in the viscera may appear engorged (filled up with blood).

**NOTE:** Free blood found in the body cavity and on the viscera (not inside the blood vessels) may be caused by improper stunning. Those carcasses are not cadavers. A thorough examination of the carcass may be necessary to make this determination.

		
05-0899 These are two adequately	10-1568 This is an adequately	03-0715 The skin over the neck on


fleshed young chickens with ample body fat, normal skin, and minimal blemishes. The carcass on the right has normal skin color. The skin over the breast, thigh, and drumstick on the carcass on the left is dark red. The red skin discoloration of the otherwise normal carcass is consistent with a bird that was still breathing when it entered the scald tank.	fleshed young turkey with ample body fat and normal skin. The skin over the entire carcass is dark red. The red skin discoloration of the otherwise normal carcass is consistent with a bird that was still breathing when it entered the scald tank.	this young chicken is dark red. A visible cut across the cervical vessels is absent. The red skin discoloration and absence of a cervical cut are consistent with a cadaver - a bird that was still breathing when it entered the scald tank. Cadavers are unfit for human food.
----------------------------------------------------------------------------------------------------------------------------------------------------------------------------------------------------------------------------------------------------------------------------------------------------------------------------------------------------------------------	-------------------------------------------------------------------------------------------------------------------------------------------------------------------------------------------------------------------------------------------------------	----------------------------------------------------------------------------------------------------------------------------------------------------------------------------------------------------------------------------------------------------------------------------------

### C. Dead on Arrival (DOA)

DOAs are birds that have died by means other than slaughter and are not allowed to be brought into the establishment. However, if DOAs are mistakenly hung on the line, they are to be removed as quickly as possible from the slaughter or evisceration line. Dead on arrival carcasses will have red to purple color and will be cool or cold to the touch. Also, the bird may have a floppy neck. The carcasses may also feel stiff and may have a foul (bad smelling) odor. DOAs are unwholesome and to be disposed of properly to ensure they are not used as human food.

#### What to Look For:

- red to purple color;
- cool or cold to the touch;
- may have a floppy neck;
- feel stiff; or
- may smell bad.

		
06-0298 This is an adequately fleshed		

<p>young chicken with ample body fat, normal skin, and minimal blemishes. The overall dark appearance evidences dehydration. The prominent dark red discoloration of one side of the carcass is suggestive of blood setting in the carcass. Depending on the ambient temperature and time since death, the carcass might be cool and/or stiff. The overall condition is consistent with a bird that was dead on arrival.</p>		
------------------------------------------------------------------------------------------------------------------------------------------------------------------------------------------------------------------------------------------------------------------------------------------------------------------------------------------------------------------------------------------------------------------------------	--	--

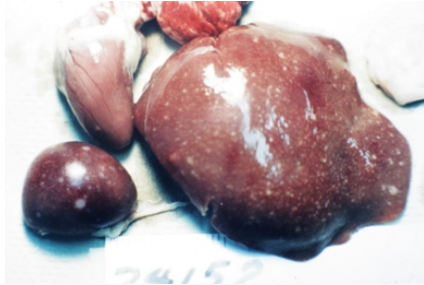
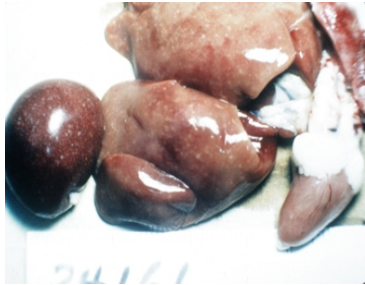
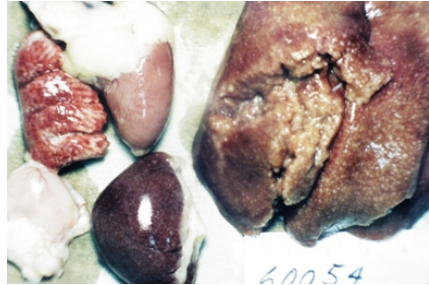
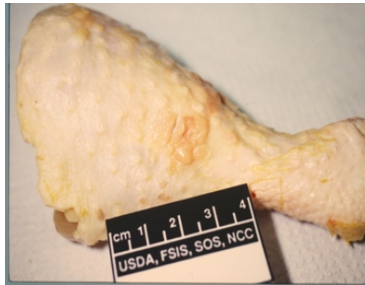

#### **D. Leukosis**

Leukosis is a tumor-causing (neoplastic) viral infection of young chickens. The tumors are seldom seen now because of the vaccination of all birds. The tumors are often small, round, well-defined white to tan nodules in the liver, spleen, or kidney. In the liver or other organs the tumors may appear as white specks. When the skin is affected, the tumors appear in the feather follicle as bumps that are round, small, and whitish to light yellow in color.

Leukosis can appear in just the viscera or just in the skin of the carcass; but any carcass affected with only one (or more) of the leukosis tumors in the skin or the viscera are unwholesome; both the carcass and its viscera must be disposed of properly to ensure they are not used as human food.

#### **What to Look For:**

- One or more tumors in the visceral organs or the skin.
- Tumors appear white to tan, small, round, and well-defined.
- Carcasses with one or more of these tumors are unwholesome, and the entire carcass and viscera must be disposed of properly as described above.

		
<p style="text-align: center;">09-0910</p> <p>This young chicken has round, white nodules, with smooth borders, throughout the liver and spleen. The heart appears normal. Such nodules are compatible with the avian leukosis complex, which is a generalized tumor condition requiring disposal of carcass and viscera.</p>	<p style="text-align: center;">09-0904</p> <p>This young chicken has round, white nodules, with smooth borders, throughout the liver and spleen. The heart appears normal. Such nodules are compatible with the avian leukosis complex, which is a generalized tumor condition requiring disposal of carcass and viscera.</p>	<p style="text-align: center;">09-0834</p> <p>This young chicken has round, white nodules, with smooth borders, throughout the liver and spleen. The heart appears normal. Such nodules are compatible with the avian leukosis complex, which is a generalized tumor condition requiring disposal of carcass and viscera .</p>
		
	<p style="text-align: center;">07-0885</p> <p>The skin of a young chicken with a round, white to tan nodule greater than one millimeter in greatest dimension, with smooth borders, centered on a</p>	<p style="text-align: center;">07-0194</p> <p>The skin of a young chicken with a round, white to tan nodule greater than one millimeter in greatest dimension, with smooth borders, centered on a feather follicle. Such a</p>

	feather follicle. Such a nodule is compatible with the avian leukosis complex, which is a generalized tumor condition requiring disposal of carcass and viscera.	nodule is compatible with the avian leukosis complex, which is a generalized tumor condition requiring disposal of carcass and viscera.
--	------------------------------------------------------------------------------------------------------------------------------------------------------------------	-----------------------------------------------------------------------------------------------------------------------------------------

## VI. LOCALIZED DISEASE OR OTHER CONDITIONS AFFECTING POULTRY CARCASSES

### A. Contamination



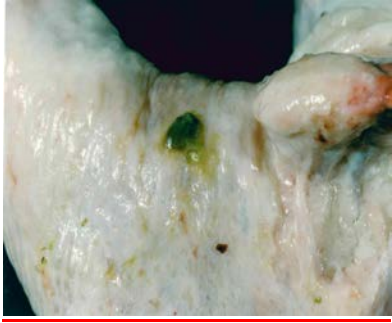
During slaughter operations, visible fecal material from the digestive tract is the main way that disease-causing bacteria can be spread to the portions of the carcass that are edible (fit to be eaten by humans). Bacteria that can cause human illness are found in the digestive tract and on the skin of birds when the birds come to slaughter. To prevent fecal material from spreading to edible portions of the carcasses, special care must be taken during handling and sanitary dressing procedures. For these reasons FSIS inspectors enforce a zero tolerance standard for visible fecal material on carcasses before the chiller. FSIS also requires that the establishment put into place effective sanitary dressing procedures throughout its slaughter process to prevent contamination of carcasses and parts.

Carcasses that are accidentally contaminated with fecal (or digestive tract) material during slaughter can be reconditioned, if they are reprocessed in a sanitary manner to remove all visible contamination by either online or offline reprocessing procedures.

**Note:** Carcasses that are excessively contaminated are unwholesome and must be disposed of properly to ensure they are not used as human food.

### What to Look For:

- Feces identification
  - Color is yellow to green, brown or white,
  - semi-solid to a paste in consistency, and
  - may or may not have plant material.
- Ingesta identification
  - Color varies with the diet,
  - Solid or granular consistency and sometimes has digestive fluids and
  - Identifiable plant material.

		
<p style="text-align: center;">10-0174</p> <p>Digestive tract content is present on the exposed muscle tissue of a young chicken. Digestive tract contents that require removal from carcass and viscera</p>	<p style="text-align: center;">10-0192</p> <p>Digestive tract content is present on the skin and exposed muscle tissue of a young chicken. Digestive tract contents that require removal from carcass and viscera</p>	<p style="text-align: center;">10-0399</p> <p>Feces is present on the skin of a young chicken. Color is green, has a semi-solid to paste consistency and does not have plant material. Feces requires removal from carcass and viscera.</p>





## B. Keratoacanthoma and Other Tumors

Keratoacanthoma and other tumors is referring to tumors other than the leukosis tumors that were previously discussed.

The most common tumor in young chickens is a keratoacanthoma, which is a tumor of the skin that looks like a miniature crater or ulcer. This tumor can range from one small tumor to many large tumors that overlap or join together (coalesce). If the carcass has so many of these tumors that they coalesce, then the entire carcass and its viscera are unwholesome and must be disposed of properly to ensure they are not used as human food. If there are only a few, smaller tumors, then the tumors can be trimmed and disposed of properly as described above. After the tumors are trimmed, the rest of the carcass can proceed down the line to the FSIS online inspector.

### What to Look For:

- Single tumors or several small tumors that are localized and can be trimmed;
- Many tumors that are intermediate to large in size and coalesce are unwholesome, and the carcass are unwholesome and must be disposed of properly as described above.




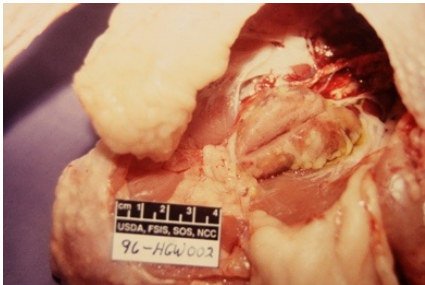
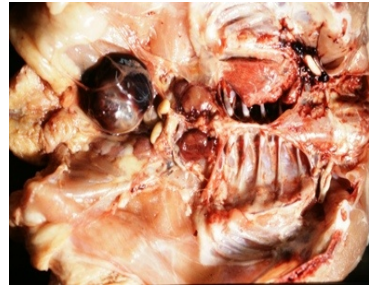
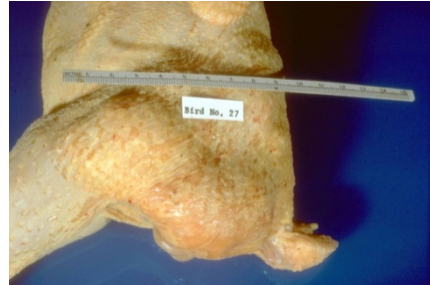
		
<p>10-1080</p> <p>This is an adequately fleshed young chicken. Several round, crater-shaped masses extend throughout the skin. Such masses are compatible with localized tumors and require trimming.</p>	<p>09-0879</p> <p>This is an adequately fleshed young chicken with coalescing, multiple, round, crater-shaped masses extending throughout the skin. Coalescing tumors require disposal of the entire carcass.</p>	

There are many other types of tumors that occur occasionally in young poultry. If one tumor is very large in size and disrupts normal body functions, for example, taking up too much space in the body then the entire carcass and viscera are unwholesome and must be disposed of properly to ensure they are not used as human food. If there is




more than one tumor of the same kind, which indicates that the tumor has spread (metastasized) then the carcass and its viscera are unwholesome and must be disposed of properly. Localized tumors can be trimmed (if just on the carcass) or all of viscera disposed of properly (if just on the viscera).

### What to Look For:

- If one very large tumor or more than one tumor of the same type, then dispose of carcass and viscera properly to ensure they are not used as human food.
- If the tumor is not very large and has not spread then trim tumor if on the carcass, or dispose of viscera only if located on the viscera.

		
<p>05-1045</p> <p>This is an adequately fleshed young chicken with a solitary mass extending out from the skin. Such a mass is compatible with a localized tumor and requires trimming.</p>	<p>09-0579</p> <p>This is an adequately fleshed young chicken. Multiple, round, white masses extend out of the skin. Such masses are compatible with localized tumors and require trimming.</p>	<p>10-1100</p> <p>This is a well-fleshed young chicken. Multiple, black masses are present in the skin. Such masses are compatible with localized tumors and require trimming.</p>
		
<p>09-0275</p>	<p>03-0681</p>	<p>10-0151</p>



<p>This is an adequately fleshed young chicken. A round, white mass extends out of the kidney. Such a mass is compatible with a localized tumor and requires trimming.</p>	<p>This is an adequately nourished young chicken with a quality defect – retained lung. A round, red mass compatible with a localized tumor extends out of the kidney and requires trimming.</p>	<p>This is a well-fleshed young chicken. A single, firm mass is present under the skin of the thigh. Such a mass is compatible with a localized tumor and requires trimming.</p>
		
<p>09-0842</p> <p>Multiple masses filled with blood are visible in the liver of this young chicken. A large ruptured mass is visible in the center of the liver. Such masses are compatible with localized tumors and require trimming.</p>	<p>10-1039</p> <p>This is a well-fleshed young chicken. A solitary mass is present in the skin. Such a mass is compatible with a localized tumor and requires trimming.</p>	<p>10-0923</p> <p>Multiple black masses are visible in the liver and lung of this young chicken. Such masses are compatible with localized tumors and requires trimming.</p>

### C. Airsacculitis

In addition to lungs, birds have balloon-like “air sacs” throughout the inside of their chest and belly (abdomen). (See **Figure 2**. In the **Appendix**.) The air sacs move the air in and out allowing the bird to breathe. When the carcasses are opened to pull out the viscera, the air sacs are torn apart, so they do not appear as balloons when being sorted. There are 6 pairs of air sacs in chickens and 5 pairs in turkeys. Normal air sacs appear very clear with thin membranes or linings. Normal air sacs are not very noticeable.

Airsacculitis is an inflammation of the air sacs that occurs when the bird is fighting off a respiratory tract infection or disease. The signs of inflammation that can be observed are a red color, swelling, and increased production of fluid. In the early (acute) stages of the disease, the air sacs can have a slight, cloudy appearance with a small amount of watery fluid, and only the air sacs are affected. If the disease has been going on for awhile (chronic), then the air sacs may appear thickened and have large amounts of




thick, white to cream-color fluid (exudate). The fluid may also have a cheesy- pus-like appearance. Other organs, such as the liver, lungs, and heart may also show these signs.




In carcasses affected with airsacculitis, all of the diseased tissues and fluids may be removed either by online or by offline salvage (vacuum or cut-up) procedures. The kidneys also must be removed and disposed of properly. If disease has spread from the air sacs to the bones of the shoulder joint, all affected tissues must be removed and disposed. After removal of affected tissues online or offline, the carcasses can go down the line to the FSIS online carcass inspector.

Carcasses with airsacculitis and signs of systemic change (Sep/Tox) are to be disposed of properly to ensure they are not used as human food. Additionally, carcasses that are extensively affected with air sac such that the inner surfaces of the carcass cannot be observed or the carcass cannot be salvaged are to be disposed of properly as described above.

### What to Look For:

- If a carcass has early stages of airsacculitis with slightly cloudy air sacs and a small amount of fluid, then the affected tissues and kidneys should be removed.
- If a carcass has thickened air sacs: large amounts of white to cream-colored fluid; or dry, yellow, cheesy pus, and the visceral organs are affected, then the affected tissues, viscera, and kidneys should be removed.
- If airsacculitis has spread from the air sacs to the bones in the shoulder joint, then the affected tissues must be removed and disposed of properly.
- If carcasses have airsacculitis and signs of systemic change (Sep/Tox) then the entire carcass and viscera are unwholesome and must be removed for proper disposal.
- If carcasses are extensively affected with airsacculitis such that the inside of the carcass cannot be observed, or the carcass cannot be salvaged, then the entire carcass and viscera must be disposed of properly as described above.

		
10-1052	10-1051	10-1054

<p>The thoracic air sac of this young chicken contains exudates, which evidence inflammation of the air sac and adjacent tissue. Inflamed tissue is unfit for human food.</p>	<p>The abdominal air sac of this young chicken contains exudates, which evidence inflammation of the air sac and adjacent tissue. Inflamed tissue is unfit for human food.</p>	<p>The abdominal air sac and sac around the heart of this young chicken contain exudates, which evidence inflammation. The general outline of the liver is not a smooth, unbroken curve, which is suggestive of fibrosis. Inflamed tissue is unfit for human food.</p>
		
<p>10-2218</p> <p>The abdominal air sac of this young turkey contains exudates, which evidence inflammation of the air sac and adjacent tissue. Inflamed tissue is unfit for human food.</p>	<p>10-1424</p> <p>The abdominal air sac of this young turkey contains exudates, which evidence inflammation of the air sac and adjacent tissue. Inflamed tissue is unfit for human food.</p>	<p>10-1074</p> <p>The abdominal air sac of this young chicken contains exudates, which evidence inflammation of the air sac and adjacent tissue. Inflamed tissue is unfit for human food.</p>




#### D. Inflammatory Process

Inflammatory Process (IP) is a term to describe inflammation in or under the skin caused by bacteria. Most often the bacteria enter through breaks in the skin caused by birds pecking one another. Usually IP appears as yellow, scabbed areas between the skin and the underlying tissues. IP may also appear as a yellow cheesy material or dried brownish flakes under the skin. In severe cases the skin will have a burnt waffle appearance. IP can occur anywhere on the bird but is most often seen around the vent, abdominal fat flaps, or side of the bird. These localized areas of infection generally can be trimmed to remove affected tissues. IP can also spread under the skin to breast muscles, and for this reason, these carcasses should be thoroughly examined to ensure that all affected portions are removed. If most of the carcass is affected by IP, then the entire carcass and viscera are unwholesome and must be disposed of properly to ensure they are not used as human food.




If the carcass affected with IP also has signs of systemic change (Sep/Tox), then the entire carcass and viscera are unwholesome and must be disposed of properly as described above.

### What to Look For:

- Localized IP: look for areas of yellow, cheesy material found in the vent area, side of the carcass, or abdominal flaps. These areas must be trimmed to remove the unwholesome tissues.
- Generalized IP: if the areas of yellow, cheesy material has travelled down to the breast, and most of the carcass is affected or the carcass shows signs of systemic change, then the entire carcass and viscera must be disposed of properly as described above.

		
<p>06-0305</p> <p>This is a well-nourished young chicken with ample body fat and no obvious blemishes. A well-defined area across the back is dark yellow to brown. Such a discoloration is compatible with inflammation. Tissue affected by inflammation is unfit for human food.</p>	<p>06-0338</p> <p>This is a well-nourished young chicken with ample body fat and no obvious blemishes. A well-defined area on the vent flap is dark yellow to brown. Such a discoloration is compatible with inflammation. Tissue affected by inflammation is unfit for human food.</p>	<p>03-0679</p> <p>The connective tissue below the skin of this young chicken contains localized exudates. The skin appears normal. Exudates evidence inflammation and inflamed tissue is unfit for human food.</p>



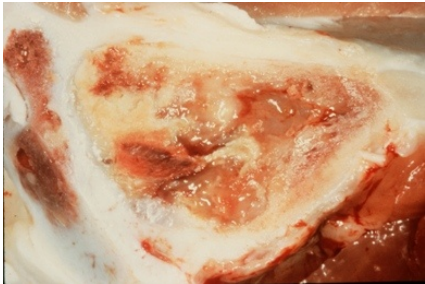


		
<p style="text-align: center;">10-1544</p> <p>This is an adequately fleshed young turkey with quality defects – surface blemishes. Feather follicles appear uniform in size and arranged in rows with approximately equal space between follicles. The scabs and open sores with red margins are consistent with inflammation</p>	<p style="text-align: center;">10-1502</p> <p>The skin of this young turkey over the drumstick appears thick, wet, and yellow. The appearance of the skin is consistent with exudates and inflammation.</p>	<p style="text-align: center;">10-1490</p> <p>This is a well-nourished young turkey with ample body fat and no obvious blemishes. The majority of the skin appears uniform in color, moist, and thick. Feather follicles appear uniform in size and arranged in rows with approximately equal space between follicles. The thick, wet, yellow appearance of the skin over the breast is consistent with exudates and inflammation.</p>

### E. Turkey Osteomyelitis Complex

Turkey Osteomyelitis Complex (TOC) affects the cartilage of bones and surrounding tissues and joints. The cause is unknown. Any bone may have TOC, but most often the knee, shoulder or hip joints are affected. The swollen joints and soft tissues may be affected mildly or more severely. A green fringed liver may indicate TOC or some other condition. Additionally, carcasses affected with TOC may not have a green liver. For each flock, special examinations are conducted by cutting into the joints to determine whether the flock is affected with TOC. If the flock is affected with TOC, then sorters should identify the carcasses and viscera with swollen joints or green livers for the establishment to perform additional procedures to remove the unwholesome tissue. All affected tissues must be removed from TOC carcasses. If it is not possible to do so, or if the carcass is showing signs of systemic change (Sep/Tox), the entire carcass and associated viscera are to be disposed of properly to ensure they are not used as human food.

### What to Look For:



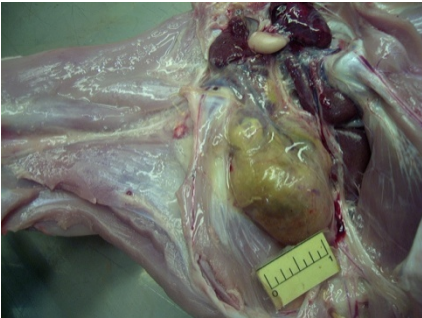


- Green fringed livers or swollen joints, especially the knee, hip, or shoulder, may indicate TOC, but it also may indicate other conditions. Carcasses are to be identified for further examination.
- Enlarged livers, soft livers with smooth surfaces, or green streaked livers may all be signs of TOC.
- Carcasses with green livers or swollen joints and with signs of systemic change are unwholesome and the carcasses and viscera must be disposed of properly.

		
03-0739 <p>The bone marrow cavity of this young turkey appears white with an open area of tan fluid. This appearance is suggestive of necrosis and exudates, which is consistent with inflammation.</p>	10-2234 <p>This fibrotic liver in a young turkey contains excess bile. The liver appears purple with white spots and blotches. The general outline is not a smooth, unbroken curve. The texture of a fibrotic liver is firm. The fibrosis and excess bile does make the liver unfit for human food.</p>	10-2256 <p>This fibrotic liver in a young turkey contains excess bile. The liver appears purple with white spots and blotches. The general outline is not a smooth, unbroken curve. The texture of a fibrotic liver is firm. The fibrosis and excess bile does make the liver unfit for human food. The fat attached to the gizzard appears thin, pink, and transparent, which is suggestive of a wasting condition.</p>

### F. Synovitis

Synovitis is inflammation of the tissues around a joint. The hock joint is most often affected. Synovitis is caused by either physical injury or infection. The joints appear swollen and may have a red or yellow appearance and contain extra visible fluid. The fluid can range from a clear watery fluid to a severe pus-like fluid that is yellowish in

color and creamy or flaky. The tendons may also be swollen. The affected legs are unwholesome and must be removed from the carcass and disposed of properly. A carcass with synovitis is wholesome unless it also shows systemic changes. If there is no systemic change, then all affected synovial tissues should be removed.

		
<p>03-0893</p> <p>The soft tissue around the joint in this young chicken is swollen. The skin appears wet and yellow. This appearance is suggestive of inflammation in the tendons and skin.</p>	<p>09-0811</p> <p>The drumstick from this young turkey has a prominent swelling under the skin. Such swelling is consistent with the presence of exudates in the underlying tendons. Inflamed tissue is unfit for human food.</p>	<p>10-1203</p> <p>A prominent greenish swelling is visible next to the kidney in this young chicken. The swelling and discoloration are consistent with the presence of exudates in the hip joint. Inflamed tissue is unfit for human food.</p>
		
	<p>10-1342</p> <p>The upper drumstick from this young turkey is normal. The lower drumstick has a</p>	<p>10-1383</p> <p>This is an adequately nourished young turkey with minimal quality defects – retained cuticle and surface</p>


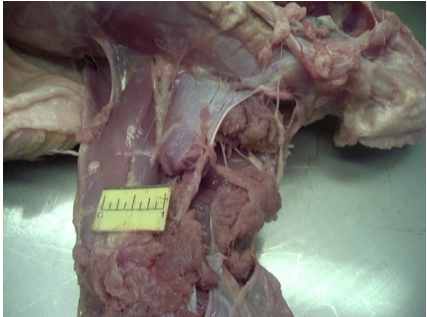
	prominent swelling of the joint and the skin is thick and yellow. Such swelling and discoloration is consistent with the presence of exudates in the underlying tendons and skin. Inflamed tissue is unfit for human food.	blemishes. A prominent swelling is visible over the thighbone. Such swelling is consistent with the presence of exudates in the underlying tendons. Inflamed tissue is unfit for human food.
--	----------------------------------------------------------------------------------------------------------------------------------------------------------------------------------------------------------------------------	----------------------------------------------------------------------------------------------------------------------------------------------------------------------------------------------

### G. Mutilation

Mutilated means the carcass is torn apart shredded or damaged by the slaughter processing equipment. Any part or organ that is mutilated and can be trimmed from the carcass is unwholesome and must be disposed of properly to ensure that it is not used as human food. If the entire carcass is affected, then the carcass is unwholesome and would be disposed of properly as described above. The viscera is wholesome and could be saved for edible product.

#### What to Look For:

- If the entire carcass is affected, then it is unwholesome and must be disposed properly as described above; but the viscera is wholesome.
- If part of the carcass is affected, then the affected tissues are unwholesome and must be trimmed and disposed of properly as described above.

		
	10-0127 The skin and muscle tissue on this young turkey is mutilated. Mutilated tissue is contaminated and unfit for	10-1254 The muscle tissue on this young turkey is mutilated. Mutilated tissue is contaminated and unfit for



	human food.	human food.
--	-------------	-------------

## **H. Overscald**

Often overscald carcasses are found after the picking line breaks down, and the carcasses are held in the scalding tank too long. When both the top breast muscle and deep breast muscle have a cooked, white, dry texture, the carcasses are unwholesome and unfit for human food and should be disposed of properly along with its associated viscera to ensure they are not used as human food.

Sometimes only the top layer of breast muscle appears white. This hard scald will likely show whitening only of the top layer of breast muscle. The hard scalded carcasses should not be disposed for overscald but should be trimmed to remove any affected tissue, and the viscera if it appears to be cooked.

### **What to Look For:**


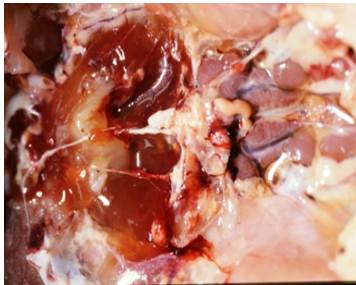
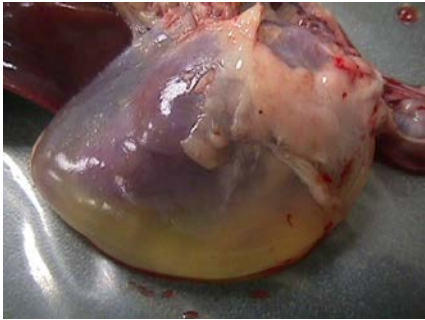
- If both top and deep breast muscles are white and appear cooked: then dispose properly as described above of the entire carcass and viscera.
- If only the top layer of breast muscle is whitened: it may be trimmed.

## **I. Ascites**

Ascites is an abnormal condition that is caused by the heart being overworked. As a result a clear to amber colored fluid collects inside the bird's body cavity (chest and abdomen). The fluid may also be found in the sac around the heart and the liver may appear swollen. It occurs in young chickens because of growing very fast.

The fluid in the body of the carcass should be removed if the inside of the cavity cannot be viewed. If the carcass shows only signs of ascites, then the viscera is unwholesome and must be disposed of properly. The carcass can go down the line to the FSIS online inspector.

If the carcass shows signs of ascites and systemic change (Sep/Tox) or any other disease condition, the entire carcass and viscera are unwholesome and must be disposed of properly to ensure the carcass and viscera are not used as human food.

		
<p style="text-align: center;">10-1862</p> <p>A clear, watery fluid is visible in the body cavity of young chicken. Such fluid retention is compatible with ascites.</p>	<p style="text-align: center;">03-0869</p> <p>Normal kidneys in a young chicken with blood tinged gelatinous fluid in the body cavity. Such fluid is compatible with ascites.</p>	<p style="text-align: center;">10-0977</p> <p>A clear, watery fluid is visible inside the capsule surrounding the heart of young chicken. Such fluid retention is compatible with ascites.</p>

## **J. Breast Atrophy**

This condition has several names, including green atrophy, green breast, and green muscle degeneration. Atrophy means “wasting away or to decrease in size.” The deep breast muscle on either one or both sides of the keel bone is affected. The condition is found mostly in broad breasted hen turkeys older than five months. The breast (on one or both sides) will appear wasted away as if it has shrunk away from the keel bone. The change in the muscle could look like a small depression or dip, or it could look very extreme or obvious. The deep muscle will be greenish in color, and it will feel hard with a wood-like texture. The breast muscle is unwholesome and must be removed and disposed of properly.

## **K. Turkey Leg Edema**







Turkey Leg Edema occurs mostly in heavy hen turkeys (older than 25 weeks) from August to October. The thigh may appear very white. The thigh will feel slick on the outside, and gas bubbles may be felt under the skin. Turkey leg edema is an inflammation of the leg. The affected leg is unwholesome and is to be disposed of properly. If there are signs of systemic change in the carcass, then the carcass and viscera are unwholesome and must be disposed of properly to ensure they are not used as human food.

## **L. Bruises**

A bruise comes from physical trauma or damage to blood vessels and the leakage of blood into the surrounding tissue. The color of a bruise varies from red to green to

black depending on the age of the bruise. Bruises that affect most or all of the whole carcass or carcasses showing signs of systemic change are unwholesome and must be disposed of properly. If bruises are localized, they may be removed by trimming.

**NOTE:** If sorters find increased numbers or clusters of severely bruised carcasses at the sorting station, this finding may be an indication that there has been a breakdown in the establishment's good commercial practices. Appropriate establishment personnel should be notified of the findings.

		
<p>10-0210</p> <p>This is a well-nourished young chicken with ample body fat and minimal blemishes. A well-defined area across the breast and wing is dark red. Such a discoloration is compatible with a bruise. Tissue affected by a bruise is unfit for human food.</p>	<p>07-0263</p> <p>This is a well-nourished young chicken with ample body fat and minimal blemishes. A well-defined area across the breast is dark red. Such a discoloration is compatible with a bruise. Tissue affected by a bruise is unfit for human food.</p>	<p>10-1625</p> <p>The skin of the hip in this young turkey is dark red. Such a discoloration is compatible with a bruise. Tissue affected by a bruise is unfit for human food.</p>
		


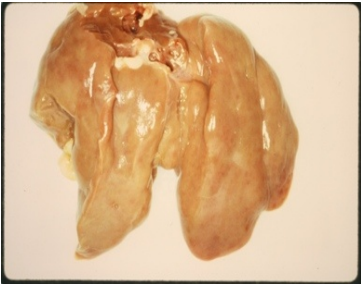


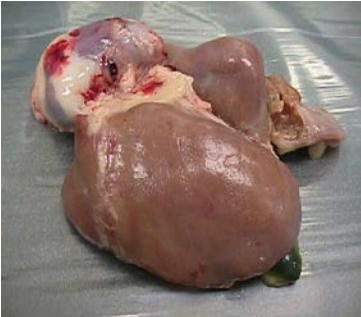

09-0661	10-0440	10-0443
The skin of this young chicken is normal with quality defects – retained feathers. A well-defined area across the back of the wing is dark red. Such a discoloration is compatible with a bruise. Tissue affected by a bruise is unfit for human food.	The skin of the drumstick in this young chicken is dark red. Such a discoloration is compatible with a bruise. Tissue affected by a bruise is unfit for human food.	The skin of the drumstick in this young chicken is dark red to green. Such a discoloration is compatible with a bruise. Tissue affected by a bruise is unfit for human food.

### **M. Parts Disposition**




Generally, when carcasses are affected with localized disease or other conditions, the affected carcass, part or viscera is unwholesome and must be disposed of properly to ensure that they are not used as human food. If the unwholesome portions or parts can be effectively removed, the remainder of the carcass is wholesome. The following are some examples of some organs or parts that are unwholesome and must be removed and disposed of properly, but the rest of carcass is wholesome.

Dispose properly to ensure the livers with the following unwholesome conditions are not to be used as human food:

- Fatty degeneration: Have visible, well defined light spots. (Livers with a uniform yellowish color throughout the liver are the result of diet and are wholesome.)
- Scar tissue due to disease (cirrhosis)
- Extensive small hemorrhages
- Inflammation (redness, swelling)
- Abscess
- Contamination from bile
- Green or other discoloration
- Granuloma
- One Leukosis tumor (also dispose of carcass and all viscera)
- One non-leukosis tumor
- Areas of necrosis (cells are dead because of death or injury)

		
<p>03-0673</p> <p>This normal liver in a young chicken contains excess fat. The liver appears tan with spots and blotches. The general outline is a smooth, unbroken curve. The texture of a fatty liver is soft. The excess fat does not make the liver unsafe or unfit for human food.</p>	<p>07-0296</p> <p>This normal liver in a young chicken contains excess fat. The liver appears tan with spots and blotches. The general outline is a smooth, unbroken curve. The texture of a fatty liver is soft. The excess fat does not make the liver unsafe or unfit for human food.</p>	<p>10-0885</p> <p>This normal liver in a young chicken contains excess fat. The liver appears tan with spots and blotches. The general outline is a smooth, unbroken curve. The texture of a fatty liver is soft. The excess fat does not make the liver unsafe or unfit for human food.</p>
		
<p>10-0929</p> <p>This inflamed liver in a young chicken is fibrotic. The liver appears reddish-brown with spots and blotches. The general outline is not a smooth, unbroken curve. The texture of an inflamed, fibrotic liver is firm to hard.</p>	<p>10-0884</p> <p>This inflamed liver in a young chicken is fibrotic and enlarged. The liver appears uniformly tan. The general outline is a smooth, unbroken curve. The texture of an enlarged, inflamed,</p>	<p>10-0821</p> <p>This inflamed liver in a young turkey is fibrotic and enlarged. The liver appears uniformly tan. The general outline is a smooth, unbroken curve. The texture of an enlarged, inflamed, fibrotic liver is hard. The</p>




The fibrosis makes the liver unfit for human food.	fibrotic liver is hard. The fibrosis makes the liver unfit for human food.	fibrosis makes the liver unfit for human food.
		
<p>03-0667</p> <p>This inflamed liver in a young chicken contains small granuloma throughout. The liver appears tan with spots and blotches. The general outline is a smooth, unbroken curve. The texture of an inflamed liver is soft to firm. The granuloma make the liver unfit for human food.</p>	<p>10-0907</p> <p>This inflamed liver in a young chicken contains small granuloma throughout. The liver appears purple with spots and blotches. The general outline is a smooth, unbroken curve. The texture of an inflamed liver is soft to firm. The granuloma make the liver unfit for human food. The slight green tinge is suggestive of bile retention.</p>	<p>10-0835</p> <p>This inflamed liver in a young turkey contains large granuloma throughout. The liver appears purple with spots and blotches. The general outline is not a smooth, unbroken curve. The texture of an inflamed liver is soft to firm. The granuloma make the liver unfit for human food. The slight green tinge is suggestive of bile retention.</p>

		
10-0779		

<p>This normal liver in a young turkey contains excess bile. The liver appears purple with green spots and blotches. The general outline is a smooth, unbroken curve. The texture of a normal liver is firm. The excess bile does make the liver unfit for human food.</p>		
----------------------------------------------------------------------------------------------------------------------------------------------------------------------------------------------------------------------------------------------------------------------------	--	--

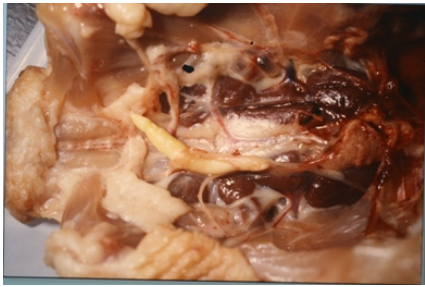


Kidneys are unwholesome and unfit and must be removed when:

- from carcasses affected with airsacculitis in the abdominal area;
- the liver is unwholesome because of disease;
- the viscera is unwholesome; or
- the kidneys are swollen.




		
<p>09-0491</p> <p>The kidneys in this young chicken are uniformly enlarged and pale in color. The uniform enlargement and color change are compatible with a growth disturbance and significant fibrosis. Tissue affected by disturbances of growth and significant fibrosis are unfit for human food.</p>		

Salpingitis: the oviduct tubes are swollen and filled with firm cheesy fluid (normally the tubes are not seen, but when infected they are visible). All affected tissues are

unwholesome and must be removed and disposed of properly. If the carcass shows signs of systemic change (Sep/Tox) then the carcass and viscera is unwholesome and must be disposed of properly.

		
<p>06-0257</p> <p>The oviduct of this young chicken contains white exudates. The oviduct is inflamed and unfit for human food.</p>	<p>09-0935</p> <p>The oviduct of this young chicken contains white exudates. The oviduct is inflamed and unfit for human food.</p>	<p>10-0694</p> <p>The oviduct of this young turkey contains white exudates. The oviduct is inflamed and unfit for human food.</p>

Pericarditis: the sac around the heart is swollen, cloudy, or filled with fluid. All affected tissues are unwholesome and must be removed and disposed of properly. If the carcass shows signs of systemic change (Sep/Tox) then the carcass and viscera is unwholesome and must be disposed of properly.

		
<p>10-0988</p> <p>This inflamed heart in a young chicken evidences the presence of exudates in the sac around the heart and on</p>	<p>10-0992</p> <p>This inflamed heart in a young chicken evidences the presence of exudates on the</p>	<p>10-0987</p> <p>This inflamed heart in a young chicken evidences the presence of exudates in the sac around the heart and on</p>



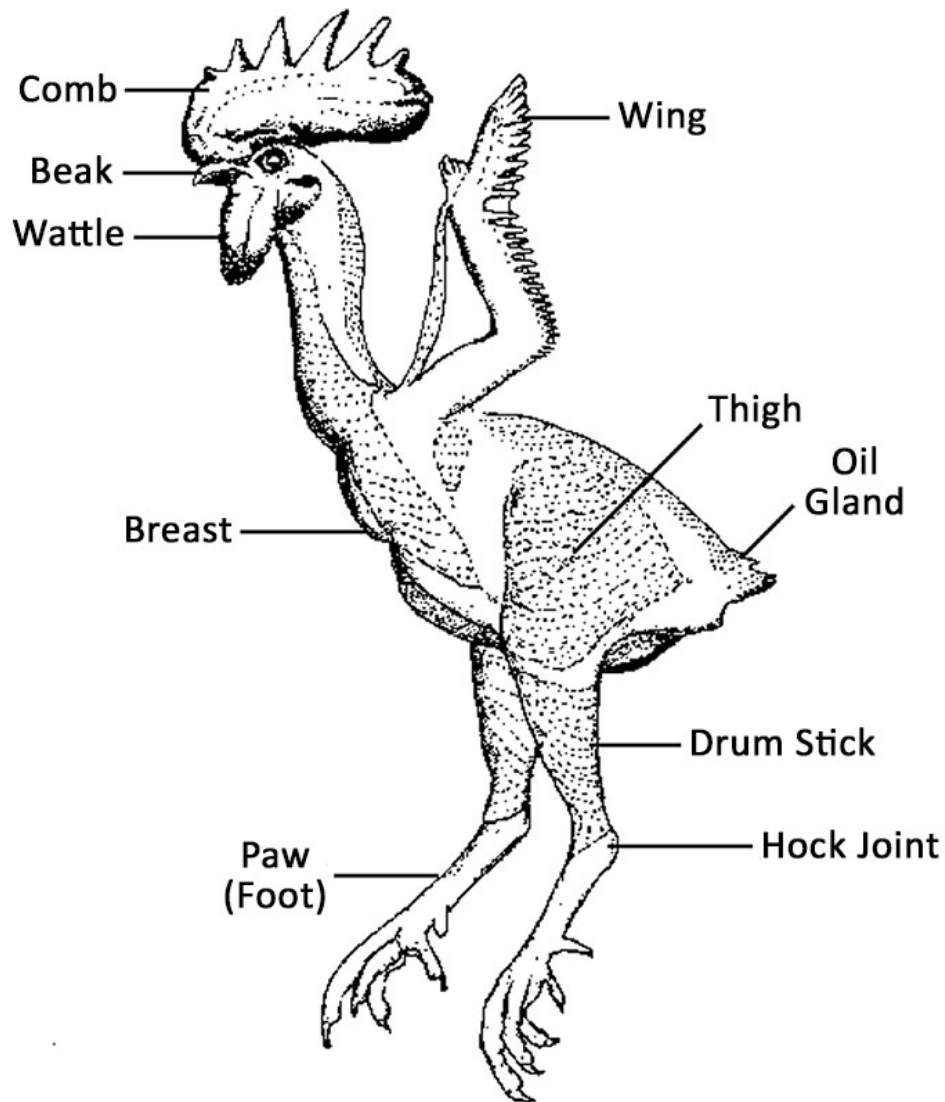
the surface of the heart. The presence of exudates makes the heart unfit for human food.	surface of the heart. The presence of exudates makes the heart unfit for human food.	the surface of the heart. The presence of exudates makes the heart unfit for human food.
------------------------------------------------------------------------------------------	--------------------------------------------------------------------------------------	------------------------------------------------------------------------------------------

## Appendix: ANATOMY OF POULTRY

Anatomy refers to the parts of a poultry bird or carcass.

### Outside (External) Anatomy

**Figure 1. Outside Anatomy** shows the parts of a chicken carcass after the feathers are removed and before the carcass is opened to remove the viscera (guts).



The **comb** and **wattles** are on the head of poultry and are largely for looks. They vary in size and color based on type and breed, and whether they are females or males.

**Snoods** and **whiskers (beards)** are external structures only found in turkeys.

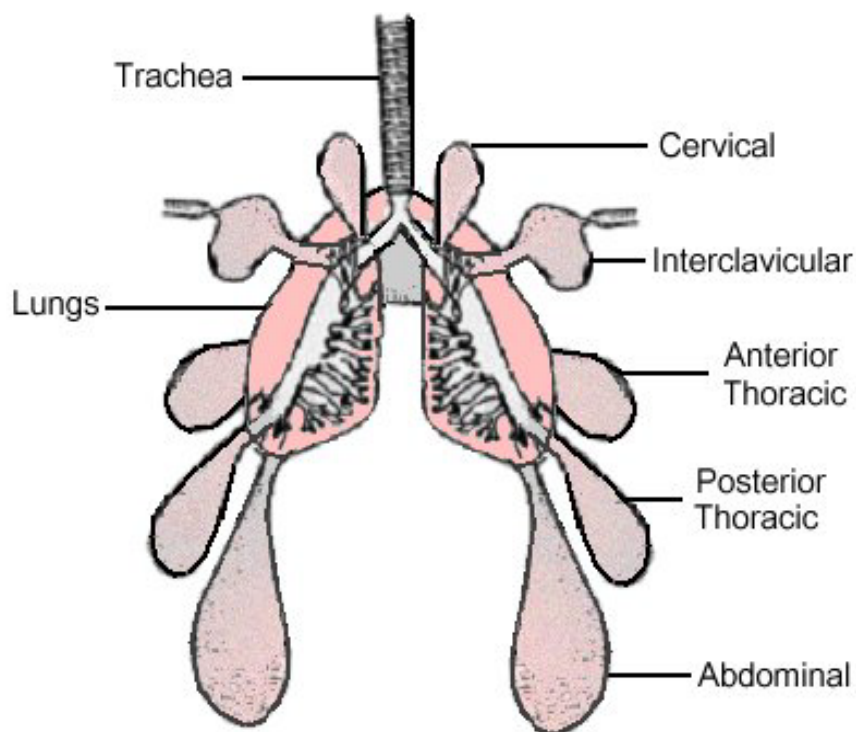
**Feathers** cover almost the entire surface of the bird. They grow from **follicles**, which are organized into groups or zones and are called **feather tracts** (see shaded areas of Figure 1).

The **skin** of chickens is thinner and more delicate than that of animals. In addition, the color of the skin depends on the type or breed of poultry, age, and diet. The skin may also be affected by the scalders used to loosen feathers.

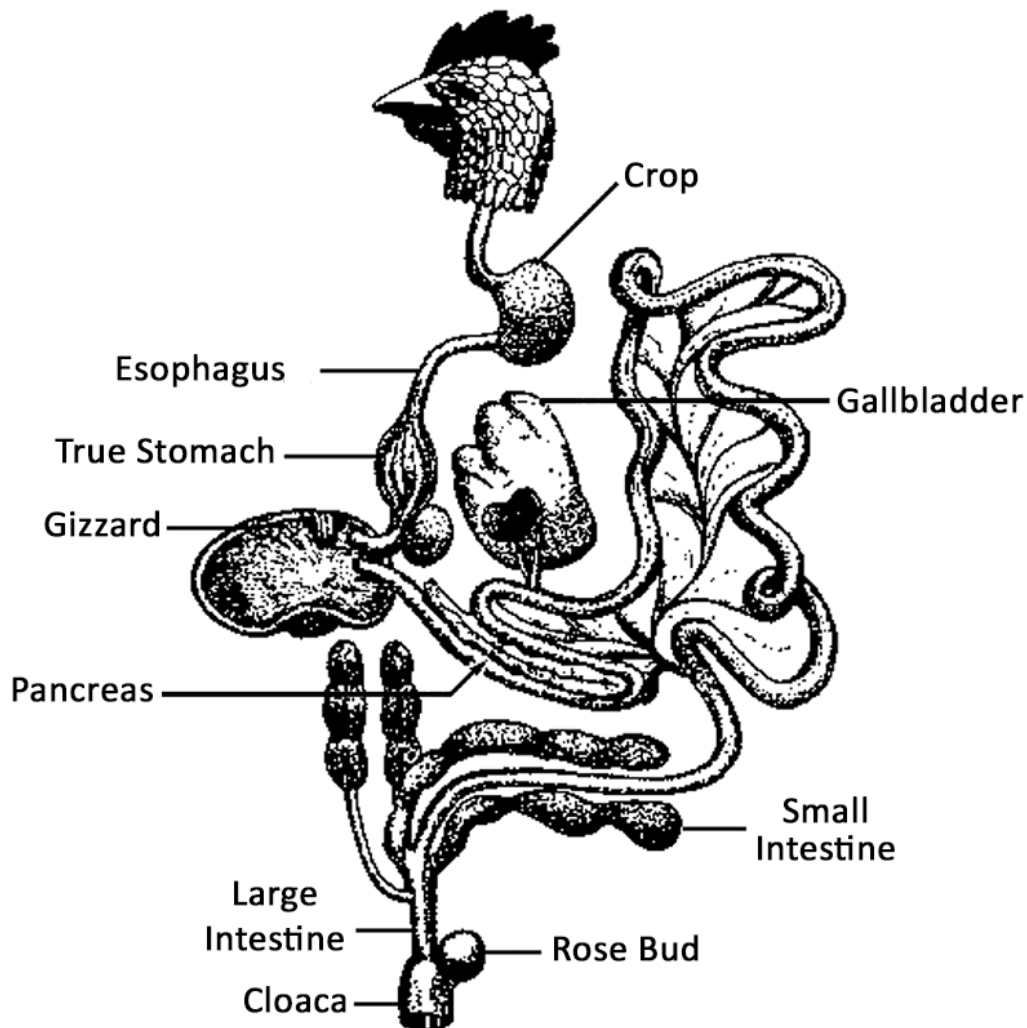
The **neck** attaches the head to the body. The **wings** are the “arms” of the bird. The **thigh** is the upper leg and the **drumstick** is the lower leg. Meat from both of them is commonly called “dark meat.” The **breast** (“white meat”) is located in the front of the bird and contains large muscles. The **hock joint** is between the lower leg and the paw. The **paws** are the feet of the bird. The **preen or oil gland** is an important gland and is located near the tip of the tail. When poultry are preening, they take oil from this gland and apply it to their feathers.

### Inside (Internal) Anatomy

The **trachea or windpipe** is the structure that carries air into the bird. Air passes through the trachea and into the air sacs. These structures are very thin, colorless membranes that when filled with air look like tiny balloons inside the body. The air sacs come in pairs, and the number of pairs is 5 in chickens and 4 in turkeys. The air sacs are round sacs that also have tiny finger like projections that go into certain bones and are shown in **Figure 2. Air Sacs**.



The **digestive tract** of the bird are shown in **Figure 3. Digestive Tract of Fowl.**



The digestive tract of the chicken begins with the mouth or **beak**, which does not contain lips or teeth. The mouth is connected to the **esophagus**, also called the **goozle** or **gullet**, which connects with the **Crop (or craw)** where feed is stored. After the crop is the stomach of birds. This stomach is called the **true stomach** (or proventriculus) and digests proteins. Next is the **gizzard** or the ventriculus. Its function is to grind the food. Often in healthy birds, there are large amounts of fat around the gizzard. The small and then large intestines come next and end at the **cloaca**. The cloaca opens to outside of the bird in an area called the **vent**. There is also a small sac on the side of the cloaca

called the **rosebud**. The rosebud is seen when the equipment cutting around the vent accidentally cuts into it.

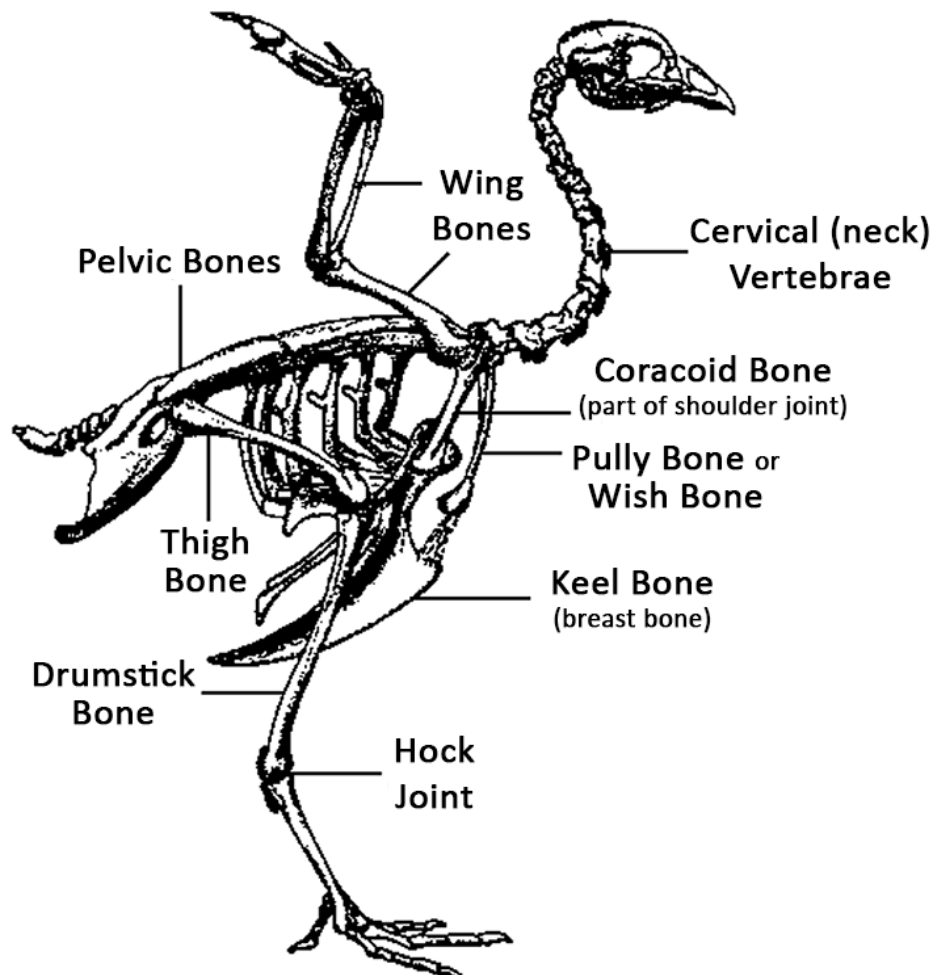
Birds that are healthy and well nourished usually have large amounts of fat throughout their tissues. The areas storing the fat are the abdominal or belly area, the vent flaps, and the gizzard and the heart.

The normal **liver** has two lobes and each lobe is drained by a bile duct. One duct is larger and makes the **gall bladder**. The color of the liver depends on the fat content or bile content.

Poultry do not contain a urinary bladder, but they do have two **kidneys**, one on each side and are set into the back bone of the bird. Ureters carry urinary waste from the kidneys to the cloaca where it leaves the bird.

### **Bones:**

The bones of chickens are shown in **Figure 4. Skeleton of domestic fowl.**





The **vertebral column** (spine) is made up of many small bones and is divided into several parts: the neck, chest, lower back or pelvic and the tail. The neck has a bone called a **wishbone** or pulley bone. The bone has two branches and an air sac lies between the two branches.

The **shoulder blade** is a bone that lies on top of each side of the rib cage. The shoulder blade with a bone from the wings and the coracoid bone makes up the **shoulder joint**.

There are several bones in the **wing**. The bones at the very end of the wing are called the **wing tip**, and it is often broken during the slaughter process.

The **knee joint** is made of the thigh bone and the drumstick. The upper leg of the chicken is the **thigh bone** just as in animals. The **drumstick** is the lower leg, again just as in animals. The next bone down from the drumstick is the **shank** bone. The **hock joint** is formed from the drumstick and the shank. The hock joint is normally opened up for sorting. The shank joins the **paws (or toes)**.

The **keel or breast bone** is a single large bone on the bottom surface of the bird.

## Image Descriptions

03-0667: This inflamed liver in a young chicken contains small granuloma throughout. The liver appears tan with spots and blotches. The general outline is a smooth, unbroken curve. The texture of an inflamed liver is soft to firm. The granuloma make the liver unfit for human food.

03-0673: This normal liver in a young chicken contains excess fat. The liver appears tan with spots and blotches. The general outline is a smooth, unbroken curve. The texture of a fatty liver is soft. The excess fat does not make the liver unsafe or unfit for human food.

03-0679: The connective tissue below the skin of this young chicken contains localized exudates. The skin appears normal. Exudates evidence inflammation and inflamed tissue is unfit for human food.

03-0681: This is an adequately nourished young chicken with a quality defect – retained lung. A round, red mass compatible with a localized tumor extends out of the kidney and requires trimming.

03-0715: The skin over the neck on this young chicken is dark red. A visible cut across the cervical vessels is absent. The red skin discoloration and absence of a cervical cut are consistent with a cadaver - a bird that was still breathing when it entered the scald tank. Cadavers are unfit for human food.

03-0732: This normal heart in a young turkey appears red with uniformly white fat where the arteries and veins attach. The surface exhibits spots and blotches. The general outline is a smooth, unbroken curve except where the arteries and veins attach.

03-0739: The bone marrow cavity of this young turkey appears white with an open area of tan fluid. This appearance is suggestive of necrosis and exudates, which is consistent with inflammation.

03-0869: Normal kidneys in a young chicken with blood tinged gelatinous fluid in the body cavity. Such fluid is compatible with ascites.

03-0893: The soft tissue around the joint in this young chicken is swollen. The skin appears wet and yellow. This appearance is suggestive of inflammation in the tendons and skin.

04-0536: This young chicken evidences necrosis and hemorrhage in the liver and spleen. The liver appears reddish-brown. The general outline is a smooth, unbroken curve. The linear white areas are soft and suggestive of dead tissue. The dark red areas in the liver and dark purple spleen are characteristic of hemorrhage. The parallel orientation of the white and dark red tissue in the liver is suggestive of swelling caused by the liver pressing against the ribs. Necrosis and hemorrhage are consistent with a generalized disease condition.

05-0899: These are two adequately fleshed young chickens with ample body fat, normal skin, and minimal blemishes. The carcass on the right has normal skin color. The skin over the breast, thigh, and drumstick on the carcass on the left is dark red. The red skin discoloration of the otherwise normal carcass is consistent with a bird that was still breathing when it entered the scald tank.

05-1045: This is an adequately fleshed young chicken with a solitary mass extending out from the skin. Such a mass is compatible with a localized tumor and requires trimming.

06-0228: This normal liver in a young turkey appears brown with light spots and blotches. The general outline is a smooth, unbroken curve. The texture of a normal liver is firm.

06-0257: The oviduct of this young chicken contains white exudates. The oviduct is inflamed and unfit for human food.

06-0298: This is an adequately fleshed young chicken with ample body fat, normal skin, and minimal blemishes. The overall dark appearance evidences dehydration. The prominent dark red discoloration of one side of the carcass is suggestive of blood setting in the carcass. Depending on the ambient temperature and time since death, the carcass might be cool and/or stiff. The overall condition is consistent with a bird that was dead on arrival.

06-0305: This is a well-nourished young chicken with ample body fat and no obvious blemishes. A well-defined area across the back is dark yellow to brown. Such a discoloration is compatible with inflammation. Tissue affected by inflammation is unfit for human food.

06-0316: The skin of this young chicken appears uniform in color, moist, and thick. Feather follicles appear uniform in size and arranged in rows with approximately equal space between follicles. The minor quality defects – feather remnant and scratches – do not make the skin unsafe or unfit for human food.

06-0338: This is a well-nourished young chicken with ample body fat and no obvious blemishes. A well-defined area on the vent flap is dark yellow to brown. Such a discoloration is compatible with inflammation. Tissue affected by inflammation is unfit for human food.

07-0159: This normal heart in a young chicken appears reddish-tan with uniformly white fat where the arteries and veins attach. The surface color appears uniform. The general outline is a smooth, unbroken curve except where the arteries and veins attach.

07-0194: The skin of a young chicken with a round, white to tan nodule greater than one millimeter in greatest dimension, with smooth borders, centered on a feather follicle. Such a nodule is compatible with the avian leukosis complex, which is a generalized tumor condition requiring disposal of carcass and viscera.

07-0242: These normal spleens from young chickens are round to oval. Their color varies from red to tan. The surface color appears uniform or exhibits spots and blotches.

07-0263: This is a well-nourished young chicken with ample body fat and minimal blemishes. A well-defined area across the breast is dark red. Such a discoloration is compatible with a bruise. Tissue affected by a bruise is unfit for human food.

07-0296: This normal liver in a young chicken contains excess fat. The liver appears tan with spots and blotches. The general outline is a smooth, unbroken curve. The texture of a fatty liver is soft. The excess fat does not make the liver unsafe or unfit for human food.

07-0564: This young chicken evidences hemorrhage in the heart. The general outline is a smooth, unbroken curve except where the arteries and veins attach. The dark red surface blotches are characteristic with hemorrhage, which is consistent with a generalized disease condition.

07-0851: This young chicken evidences adequate body fat and normal skin. The enlarged joint at the end of the drumstick is suggestive of inflammation. The uniformly dark muscle tissue is suggestive of extreme loss of body fluids. Inflammation with loss of body fluids are compatible with wasting, which is a generalized disease condition.

07-0877: This is a well-nourished young chicken with ample body fat and minimal blemishes. The body is plump. The general form of the wings and hips is round. The skin appears uniform in color, moist, and thick. The underlying muscle tissue is barely visible through the skin. The yellow color is due to yellow plant pigments in the feed.

07-0885: The skin of a young chicken with a round, white to tan nodule greater than one millimeter in greatest dimension, with smooth borders, centered on a feather follicle. Such a nodule is compatible with the avian leukosis complex, which is a generalized tumor condition requiring disposal of carcass and viscera.

09-0275: This is an adequately fleshed young chicken. A round, white mass extends out of the kidney. Such a mass is compatible with a localized tumor and requires trimming.

09-0491: The kidneys in this young chicken are uniformly enlarged and pale in color. The uniform enlargement and color change are compatible with a growth disturbance and significant fibrosis. Tissue affected by disturbances of growth and significant fibrosis are unfit for human food.

09-0579: This is an adequately fleshed young chicken. Multiple, round, white masses extend out of the skin. Such masses are compatible with localized tumors and require trimming.

09-0625: This young turkey evidences necrosis in the liver. The liver appears red. The general outline is a smooth, unbroken curve. The linear white areas are soft and suggestive of dead tissue. The parallel orientation of the white tissue is suggestive of swelling caused by the liver pressing against the ribs. Necrosis is consistent with a generalized disease condition.

09-0661: The skin of this young chicken is normal with quality defects – retained feathers. A well-defined area across the back of the wing is dark red. Such a discoloration is compatible with a bruise. Tissue affected by a bruise is unfit for human food.

09-0690: These normal livers from two young turkeys appear reddish-brown with lights spots and blotches. The general outline is a smooth, unbroken curve. The dry appearance of the liver on the left is a post mortem artifact. The texture of a normal liver is firm.

09-0691: These two normal hearts from two young turkeys appear red with uniformly white fat where the arteries and veins attach. The surface exhibits spots and blotches. The general outline is a smooth, unbroken curve except where the arteries and veins attach.

09-0693: These normal spleens from young turkeys are round to oval. Their color varies from red to tan. The surface color appears uniform or exhibits spots and blotches.

09-0794: This normal bone marrow from a young turkey appears uniformly red with a fine texture.

09-0811: The drumstick from this young turkey has a prominent swelling under the skin. Such swelling is consistent with the presence of exudates in the underlying tendons. Inflamed tissue is unfit for human food.

09-0834: This young chicken has round, white nodules, with smooth borders, throughout the liver and spleen. The heart appears normal. Such nodules are compatible with the avian leukosis complex, which is a generalized tumor condition requiring disposal of carcass and viscera.

09-0842: Multiple masses filled with blood are visible in the liver of this young chicken. A large ruptured mass is visible in the center of the liver. Such masses are compatible with localized tumors and requires trimming..

09-0879: This is an adequately fleshed young chicken with coalescing,multiple, round, crater-shaped masses extending throughout the skin. Coalescing tumors require disposal of the entire carcass

09-0904: This young chicken has round, white nodules, with smooth borders, throughout the liver and spleen. The heart appears normal. Such nodules are compatible with the avian

leukosis complex, which is a generalized tumor condition requiring disposal of carcass and viscera.

09-0910: This young chicken has round, white nodules, with smooth borders, throughout the liver and spleen. The heart appears normal. Such nodules are compatible with the avian leukosis complex, which is a generalized tumor condition requiring disposal of carcass and viscera.

09-0921: This young chicken evidences necrosis in the liver and hemorrhage in the spleen. The liver is soft with white blotches suggestive of dead tissue. The general outline is a smooth, unbroken curve. The dark purple and soft spleen is characteristic of hemorrhage. The heart appears normal. Necrosis and hemorrhage are consistent with a generalized disease condition.

09-0935: The oviduct of this young chicken contains white exudates. The oviduct is inflamed and unfit for human food.

10-0127: The skin and muscle tissue on this young turkey is mutilated. Mutilated tissue is contaminated and unfit for human food.

10-0151: This is a well-fleshed young chicken. A single, firm mass is present under the skin of the thigh. Such a mass is compatible with a localized tumor and requires trimming

10-0174: Digestive tract content is present on the exposed muscle tissue of a young chicken. Digestive tract contents require removal from the carcass and viscera.

10-0192: Digestive tract content is present on the skin and exposed muscle tissue of a young chicken. Digestive tract contents require removal from the carcass and viscera. 10-0210: This is a well-nourished young chicken with ample body fat and minimal blemishes. A well-defined area across the breast and wing is dark red. Such a discoloration is compatible with a bruise. Tissue affected by a bruise is unfit for human food.

10-0236: This normal joint surface and tendon in a young chicken are white. The surface is shiny.

10-0399: Feces is present on the skin of a young chicken. Color is green, has a semi-solid to paste consistency and does not have plant material. Feces requires removal from carcass and viscera.

10-0403: The skin of this young chicken appears uniform in color, moist, and thick. Feather follicles appear uniform in size and arranged in rows with approximately equal space between follicles. The minor quality defects – feather remnants and red blemishes – do not make the skin unsafe or unfit for human food.

10-0440: The skin of the drumstick in this young chicken is dark red. Such a discoloration is compatible with a bruise. Tissue affected by a bruise is unfit for human food.

10-0443: The skin of the drumstick in this young chicken is dark red to green. Such a discoloration is compatible with a bruise. Tissue affected by a bruise is unfit for human food.

10-0694: The oviduct of this young turkey contains white exudates. The oviduct is inflamed and unfit for human food.

10-0706: The heart of this young turkey appears wet, and off-white. The fat, normally visible where the arteries and veins attach, is gone. The general outline is no longer a smooth, unbroken curve. This is compatible with wasting, which is a generalized disease condition.

10-0779: This normal liver in a young turkey contains excess bile. The liver appears purple with green spots and blotches. The general outline is a smooth, unbroken curve. The texture of a normal liver is firm. The excess bile does make the liver unfit for human food.



10-0821: This inflamed liver in a young turkey is fibrotic and enlarged. The liver appears uniformly tan. The general outline is a smooth, unbroken curve. The texture of an enlarged, inflamed, fibrotic liver is hard. The fibrosis makes the liver unfit for human food.

10-0835: This inflamed liver in a young turkey contains large granuloma throughout. The liver appears purple with spots and blotches. The general outline is not a smooth, unbroken curve. The texture of an inflamed liver is soft to firm. The granuloma make the liver unfit for human food. The slight green tinge is suggestive of bile retention.

10-0866: The fat attached to the gizzard of this young turkey appears thin, pink, and transparent. This is compatible with wasting, which is a generalized disease condition.

10-0884: This inflamed liver in a young chicken is fibrotic and enlarged. The liver appears uniformly tan. The general outline is a smooth, unbroken curve. The texture of an enlarged, inflamed, fibrotic liver is hard. The fibrosis makes the liver unfit for human food.

10-0885: This normal liver in a young chicken contains excess fat. The liver appears tan with spots and blotches. The general outline is a smooth, unbroken curve. The texture of a fatty liver is soft. The excess fat does not make the liver unsafe or unfit for human food.

10-0907: This inflamed liver in a young chicken contains small granuloma throughout. The liver appears purple with spots and blotches. The general outline is a smooth, unbroken curve. The texture of an inflamed liver is soft to firm. The granuloma make the liver unfit for human food. The slight green tinge is suggestive of bile retention.

10-0923: Multiple black masses are visible in the liver and lung of this young chicken. Such masses are compatible with localized tumors and require trimming.

10-0929: This inflamed liver in a young chicken is fibrotic. The liver appears reddish-brown with spots and blotches. The general outline is not a smooth, unbroken curve. The texture of an inflamed, fibrotic liver is firm to hard. The fibrosis makes the liver unfit for human food.

10-0977: A clear, watery fluid is visible inside the capsule surrounding the heart of young chicken. Such fluid retention is compatible with ascites.

10-0987: This inflamed heart in a young chicken evidences the presence of exudates in the sac around the heart and on the surface of the heart. The presence of exudates makes the heart unfit for human food.

10-0988: This inflamed heart in a young chicken evidences the presence of exudates in the sac around the heart and on the surface of the heart. The presence of exudates makes the heart unfit for human food.

10-0992: This inflamed heart in a young chicken evidences the presence of exudates on the surface of the heart. The presence of exudates makes the heart unfit for human food.

10-1039: This is a well-fleshed young chicken. A solitary mass is present in the skin. Such a mass is compatible with a localized tumor and require trimming.

10-1044: The normal thoracic air sac in this young chicken appears thin, pliable, and somewhat transparent. The minor quality defect – lung – does not make the carcass unsafe or unfit for human food.

10-1046: The normal thoracic air sac in this young chicken appears thin, pliable, and somewhat transparent.

10-1051: The abdominal air sac of this young chicken contains exudates, which evidence inflammation of the air sac and adjacent tissue. Inflamed tissue is unfit for human food.

10-1052: The thoracic air sac of this young chicken contains exudates, which evidence inflammation of the air sac and adjacent tissue. Inflamed tissue is unfit for human food.

10-1054: The abdominal air sac and sac around the heart of this young chicken contain exudates, which evidence inflammation. The general outline of the liver is not a smooth, unbroken curve, which is suggestive of fibrosis. Inflamed tissue is unfit for human food.

10-1074: The abdominal air sac of this young chicken contains exudates, which evidence inflammation of the air sac and adjacent tissue. Inflamed tissue is unfit for human food.

10-1080: This is an adequately fleshed young chicken. Several , round, crater-shaped masses extend throughout the skin. Such masses are compatible with localized tumors and require trimming.

10-1100: This is a well-fleshed young chicken. Multiple, black masses are present in the skin. Such masses are compatible with localized tumors and require trimming.

10-1161: The skin of this young chicken appears uniform in color, moist, and thick. Feather follicles appear uniform in size and arranged in rows with approximately equal space between follicles. The minor quality defects – red blemishes – do not make the skin unsafe or unfit for human food.

10-1203: A prominent greenish swelling is visible next to the kidney in this young chicken. The swelling and discoloration are consistent with the presence of exudates in the hip joint. Inflamed tissue is unfit for human food.

10-1232: This normal joint surface and tendon in a young turkey are white. The surface is shiny.

10-1254: The muscle tissue on this young turkey is mutilated. Mutilated tissue is contaminated and unfit for human food.

10-1257: This young turkey evidences inadequate body fat and normal skin. The prominent thighbone and uniformly dark muscle tissue are compatible with wasting, which is consistent with a generalized disease condition.

10-1318: This is an adequately nourished young turkey with adequate body fat and minimal blemishes. The body is slender. The general form of the wings and sternum is angular. The skin appears uniform in color, moist, and thin. The underlying muscle tissue is visible through the skin.

10-1320: This is a well-nourished young turkey with ample body fat and minimal blemishes. The body is plump. The general form of the wings and hips is round. The skin appears uniform in color, moist, and thick. The underlying muscle tissue is barely visible through the skin.

10-1324: This is a well-nourished young turkey with ample body fat and minimal blemishes. The body is plump. The general form of the wings and hips is round. The skin appears uniform in color, moist, and thick. The underlying muscle tissue is barely visible through the skin.

10-1342: The upper drumstick from this young turkey is normal. The lower drumstick has a prominent swelling of the joint and the skin is thick and yellow. Such swelling and discoloration is consistent with the presence of exudates in the underlying tendons and skin. Inflamed tissue is unfit for human food.

10-1352: This young turkey evidences inadequate body fat and normal skin. The linear, red blemishes in the skin are veins filled with blood. The prominent thighbone and uniformly dark muscle tissue are compatible with wasting, which is consistent with a generalized disease condition.

10-1383: This is an adequately nourished young turkey with minimal quality defects – retained cuticle and surface blemishes. A prominent swelling is visible over the thighbone. Such swelling is consistent with the presence of exudates in the underlying tendons. Inflamed tissue is unfit for human food.

10-1424: The abdominal air sac of this young turkey contains exudates, which evidence inflammation of the air sac and adjacent tissue. Inflamed tissue is unfit for human food.

10-1465: This is a well-nourished young chicken with ample body fat and no obvious blemishes. The skin appears uniform in color, moist, and thick. Feather follicles appear uniform in size and arranged in rows with approximately equal space between follicles.

10-1490: This is a well-nourished young turkey with ample body fat and no obvious blemishes. The majority of the skin appears uniform in color, moist, and thick. Feather follicles appear uniform in size and arranged in rows with approximately equal space between follicles. The thick, wet, yellow appearance of the skin over the breast is consistent with exudates and inflammation.

10-1502: The skin of this young turkey over the drumstick appears thick, wet, and yellow. The appearance of the skin is consistent with exudates and inflammation.

10-1532: The skin of this young turkey appears uniform in color, moist, and thick. Feather follicles appear uniform in size and arranged in rows with approximately equal space between follicles. The minor quality defects – surface blemishes – do not make the skin unsafe or unfit for human food.

10-1544: This is an adequately fleshed young turkey with quality defects – surface blemishes. Feather follicles appear uniform in size and arranged in rows with approximately equal space between follicles. The scabs and open sores with red margins are consistent with inflammation.

10-1568: This is an adequately fleshed young turkey with ample body fat and normal skin. The skin over the entire carcass is dark red. The red skin discoloration of the otherwise normal carcass is consistent with a bird that was still breathing when it entered the scald tank.

10-1606: The skin of this young turkey appears uniform in color, moist, and thick. Feather follicles appear uniform in size and arranged in rows with approximately equal space between follicles. The minor quality defects – retained cuticle and feather remnant – do not make the skin unsafe or unfit for human food.

10-1625: The skin of the hip in this young turkey is dark red. Such a discoloration is compatible with a bruise. Tissue affected by a bruise is unfit for human food.

10-1807: This normal liver in a young chicken appears reddish-purple with light spots and blotches. The general outline is a smooth, unbroken curve. The texture of a normal liver is firm. The normal fat attached to the gizzard appears uniformly white and completely opaque.

10-1822: This is a well-nourished young chicken with ample body fat and no obvious blemishes. The body is plump. The general form of the wings and hips is round. The skin appears uniform in color, moist, and thick. The underlying muscle tissue is barely visible through the skin.

10-1846: This is an adequately nourished young chicken with adequate body fat and minimal blemishes. The body is slender. The general form of the wings and sternum is angular. The skin appears uniform in color, moist, and thin. The underlying muscle tissue is visible through the skin.

10-1862: A clear, watery fluid is visible in the body cavity of young chicken. Such fluid retention is compatible with ascites.

10-1901: This young chicken evidences adequate body fat and normal skin. The uniformly dark muscle tissue is suggestive of an extreme loss of body fluids, which is consistent with a generalized disease condition.

10-1950: This young chicken evidences inadequate body fat and normal skin. The prominent keel bone and uniformly dark muscle tissue are compatible with wasting, which is consistent with a generalized disease condition.

10-2017: This young chicken evidences necrosis in the liver. The liver appears red. A significant portion of the liver is pink. Exudates are visible on the surface. The general outline is a smooth, unbroken curve. Necrosis with exudates is consistent with a generalized disease condition. The yellow color of the fat is due to yellow plant pigments in the feed.

10-2218: The abdominal air sac of this young turkey contains exudates, which evidence inflammation of the air sac and adjacent tissue. Inflamed tissue is unfit for human food.

10-2223: The normal thoracic and abdominal air sacs in this young turkey appear thin, pliable, and somewhat transparent.

10-2234: This fibrotic liver in a young turkey contains excess bile. The liver appears purple with white spots and blotches. The general outline is not a smooth, unbroken curve. The texture of a fibrotic liver is firm. The fibrosis and excess bile does make the liver unfit for human food.

10-2256: This fibrotic liver in a young turkey contains excess bile. The liver appears purple with white spots and blotches. The general outline is not a smooth, unbroken curve. The texture of a fibrotic liver is firm. The fibrosis and excess bile does make the liver unfit for human food. The fat attached to the gizzard appears thin, pink, and transparent, which is suggestive of a wasting condition.